

Report on treatment with Visalys® Fill and Visalys® Flow

Dr. Susanne Busch, June 2023

Dental treatment from a patient perspective

Filling with the new Visalys® Fill and Visalys® Flow composites – a self-experiment

Honestly? I don't like going to the dentist. But I have been working with teeth and restorative materials for 30 years as part of my job: first in my PhD as a chemist, then as a developer of restorative materials, and recently as a product manager for the Visalys® line at Kettenbach Dental. And to allow me to stand behind my products with complete conviction, I thought it only fair and reasonable to try them out myself. Hence the self-experiment that I have described below.

I have had various amalgam fillings in my molars since I was a child. What's amazing about these fillings is that some are still intact, but their unsightliness has been annoying me for over 40 years. I am also finding the idea of walking around with a hazardous waste pile in my mouth increasingly unpleasant. In Dr. Seidler I have now found a dentist who I can trust and so asked her to replace two class I amalgam fillings with an attractive composite.

The **Visalys® Fill** and **Visalys® Flow** restorative materials launched on the market in March this year, both nano-hybrid composites with excellent strength and long-term stability, as well as an innovative shade system were used. Due to the exceptional chameleon effect, only five shades are needed to esthetically restore teeth in all sixteen Vita shades. The opaque shade OA2 should be used to cover stains, while a bleach shade is used for visually brightened teeth.

In my case, Dr. Seidler selected shade A3. Once the necessary rubber dam had been positioned (I found it very unpleasant as it proved difficult to fasten due to the tight grouping of my teeth), the fillings in teeth 46 and 47 were removed and the typical buzzing of the drill once again reminded me why I prefer to avoid dental practices. Luckily, the fillings were level enough at two mm to get away with less anesthesia and a certain amount of willingness to suffer. My wish was to have the work done as minimally invasively as possible, which also happened to be Dr. Seidler's philosophy. So the heavily stained, but firm dentin was left in place and, after etching and bonding, covered with an

initial layer of opaque OA2. At first, Dr. Seidler was doubtful whether the blackish amalgam staining could even be concealed with such a shallow filling and I asked myself whether minimally invasive and esthetic may be mutually exclusive concepts. But these concerns proved to be unjustified. Once the filling had been put in place and finished, the result was surprisingly attractive: absolutely no trace of the staining. Because I grind my teeth when I'm stressed, my molars are already quite abraded, meaning that Dr. Seidler was not able to model distinct cusps without an excessively raised occlusion. Despite this, the result is impressive and certainly lives up to all my expectations!

This also gave me the courage to entrust Dr. Seidler with another problem: The exposed cervical dentin on teeth 35 and 36 have long been an irritation. While they were not painful, they were unesthetic. Could this be a job for **Visalys® Flow**? Dr. Seidler selected an A3.5, once again with the OA2 underneath and, as if by magic, the exposed cervical dentin disappeared. While you can see where the fillings have been placed in the close-ups, they are invisible in the mirror, and that is what's important to me. A few days later I have the impression that the fillings are even more esthetic. I suspect that the tooth enamel, which was initially comprehensively dried during the placement of the filling, has now recovered and resulted in an even better integration of the filling.

In summary, I can say that I find it very enriching to be able to report on my own experience and tell you just how esthetic fillings with **Visalys® Fill** and **Visalys® Flow** can be. I am now in a position where I can recommend this material as both a product manager and a patient in good conscience.

Acknowledgment: I would like to thank Dr. Seidler and her team for their outstanding work. My thanks also to Mr. Reichel from arifoto for his photos.

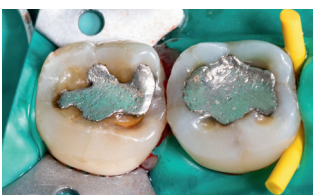


Fig. 1: Before: starting situation, shallow amalgam fillings in 46 and 47

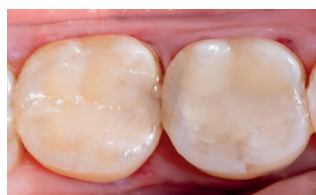

Fig. 2: After: finished fillings after occlusal adjustment

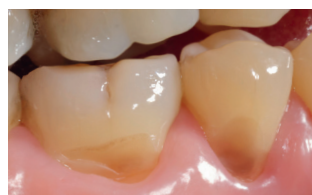

Fig. 3: Before: Exposed cervical dentin at 35 and 36

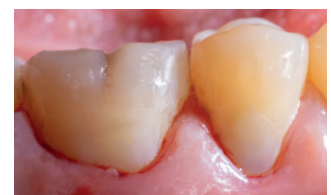

Fig. 4: After: Finished cervical restorations